Percutaneous Image-guided Cryoneurolysis: Applications and Techniques

Alan Alper Sag, MD
Ross Bittman, MD
Frank Prologo, BS
Eric B. Friedberg, MD
Nariman Nezami, MD
Sana Ansari, MD
J. David Prologo, MD

Abbreviations: CMS = Centers for Medicare and Medicaid Services, CPT = *Current Procedural Terminology*

RadioGraphics 2022; 42:1776–1794

https://doi.org/10.1148/rg.220082

Content Codes: IR VA

From the Division of Vascular and Interventional Radiology, Department of Radiology, Duke University Medical Center, 2301 Erwin Road, DUMC Box 3808, Durham, NC 27710 (A.A.S.); Department of Radiology and Imaging Sciences, Division of Interventional Radiology and Image Guided Medicine (R.B., E.B.F., J.D.P.), Division of Female Pelvic Medicine and Reconstructive Surgery, Department of Gynecology and Obstetrics (S.A.), Emory University School of Medicine, Atlanta, Ga; Department of Biological Sciences. Clemson University, Clemson, SC (F.P.); Division of Vascular and Interventional Radiology, Department of Diagnostic Radiology and Nuclear Medicine, University of Maryland School of Medicine, Baltimore, Md (N.N.); and Experimental Therapeutics Program, University of Maryland Marlene and Stewart Greenebaum Comprehensive Cancer Center, Baltimore, Md (N.N.). Presented as an education exhibit at the 2020 RSNA Annual Meeting. Received April 10, 2022; revision requested June 22 and received July 12; accepted July 14. For this journal-based SA-CME activity, the authors E.B.F., N.N., and J.D.P. have provided disclosures (see end of article); all other authors, the editor, and the reviewers have disclosed no relevant relationships. **Address correspondence to** A.A.S. (email: *alan.sag@duke.edu*).

©RSNA, 2022

SA-CME LEARNING OBJECTIVES

After completing this journal-based SA-CME activity, participants will be able to:

- Discuss the rationale of a diagnostic nerve block as a confirmatory test before cryoneurolysis.
- List the category III CPT codes assigned by CMS to cryoneurolysis.
- Describe the range of visceral and somatic targets available for cryoneurolysis.

See rsna.org/learning-center-rg.

The expansion and dissemination of interventional cryoneurolysis in recent years has been fueled by the integration of advanced imaging guidance, the evolution of our understanding of neuropathologic processes after exposure of nerves to cold, and opportunities for its use beyond pain management. The clinical translation of cryoneurolysis through interventional radiology requires consideration of many factors, including *(a)* the supply and composition of target nerves, *(b)* the value of diagnostic injection with imaging guidance for confirmation, (c) the integration of advanced imaging guidance that allows safe ablation, *(d)* the difference between neoplastic and nonneoplastic causes of pain, *(e)* the phenomenon of percutaneously induced neuroregeneration, *(f)* the potential to manage conditions other than pain, *(g)* the consideration of protocols, *(h)* the limitations of current technology, and *(i)* the potential complications and adverse effects. Cryoneurolysis has societal and legislative endorsement as an effective nonopioid option for pain palliation. The Centers for Medicare and Medicaid Services (CMS) approved three new category III *Current Procedural Terminology* (CPT) codes specifically for the cryoablation of nerves with advanced imaging guidance. Interventional radiologists who are aware of nerve-directed strategies see eligible patients in their daily practice and have opportunities to bundle procedures (eg, celiac plexus block at the time of a biliary drain for pancreatic cancer with low bile duct obstruction), offering an avenue to serve the patient, reduce opioid dependence, allow faster discharge, and establish name recognition of interventional radiologists. Also, the ability to use CT to target deep structures accurately and swiftly, often with only local anesthesia, compared with the usual monitored anesthesia care in a surgical setting, may provide another avenue to build a cryoneurolysis practice.

©RSNA, 2022 • *radiographics.rsna.org*

Introduction

The use of prescription opioids in health care institutions exposes patients to the risk of dependence, abuse, addiction, and overdose and contributes to the global opioid epidemic. Legislative bodies and societal commissions have directed clinicians toward opioid alternatives, including cryoneurolysis (1). The integration of advanced imaging guidance, the evolution of our understanding of neuropathologic processes that occur after exposure of nerves to cold, and the opportunities to expand its use beyond pain management have fueled the expansion and dissemination of interventional cryoneurolysis in recent years (2). Cryoablation offers the benefit of controlled delivery with less risk of nontarget injury when compared with administration of liquid neurolytics and offers several benefits over radiofrequency ablation neurotomy, including less intra- and postprocedural pain; visualization of the ablation zone, with ice ball growth in real time; and the lack of

TEACHING POINTS

- Cryoneurolysis has societal and legislative endorsement as an effective nonopioid procedural option for pain palliation.
- The creation of a Sunderland 2 injury when targeting peripheral nerves with cryoneurolysis is a critical component for clinical success and predictable outcomes.
- Historically, dissemination of uniform protocols and outcomes has been limited by unknown in vivo temperature, improper cross-sectional area of coverage, adjacent blood flow, depth of the target area, nerve size and/or composition variability, and/or operator conservatism in the absence of established times and/or temperatures.
- The pudendal nerves are classic targets, because they meet the key considerations necessary for cryoneurolysis, including attention to the supply and composition of target nerves, diagnostic injection with cross-sectional imaging, advanced imaging guidance that allows ablation, neoplastic versus nonneoplastic cause of pain, percutaneously induced neuroregeneration, the potential to manage conditions other than pain, protocol considerations, and potential complications or adverse effects.
- Interventional cryoneurolysis also may be useful for myriad nerve-mediated clinical conditions that are not pain related.

electromagnetic field interaction with pacemakers. Cryoneurolysis has societal and legislative endorsement as an effective nonopioid procedural option for pain palliation.

History of Cryoneurolysis

Although cold therapy has been used as an analgesic for hundreds of years, the first closed cryoablation device, using liquid nitrogen as the refrigerant, was developed for clinical care by a neurosurgeon named Irving Cooper in 1961 (3). This device was used to create lesions in the thalamus for the treatment of Parkinson disease, with good success compared with other available treatments. In 1976, Lloyd et al (4) published the first study of percutaneous cryoneurolysis using a cryoablation probe coupled to a nerve stimulator to target a variety of peripheral nerves in 64 patients. The results were positive, and in the following decade, large case series (5,6) showed the efficacy of cryoneurolysis under fluoroscopic guidance for the treatment of intercostal and perineal pain. Imaging and ablative technologies continued to evolve, and the body of evidence supporting the use of cryoneurolysis for the management of pain expanded (2,7–9).

Bench-to-Clinical Translation of Cryoneurolysis

Grading systems for nerve injury such as those described by Sunderland and Seddon are included in Table 1. Table 2 shows the terminology of cryoneurolysis used in this article. The exposure of nerves to temperatures lower than −20°C but warmer than −100°C is the historically published benchmark for inducing Sunderland 2 peripheral nerve injury (ie, myelinolysis and axonolysis) during cryoneurolysis (10–12). The importance of the Sunderland grade 2 injury cannot be overstated. When a precise amount of energy is removed from a targeted area that includes nerve cooling, the following sequence of events is induced: intracellular ice crystal formation, microtubule dissolution, and wallerian degeneration, followed by predictable axonal regeneration along an uninterrupted connective tissue scaffold (13–15). When it is successfully achieved, cryoneurolysis allows appropriate management of patient expectations, longer pain relief compared with that of local injections or temporary catheter infusions, and a lower risk of formation of neuromas compared with that of heat-mediated ablation or surgical transection (15–21). The creation of a Sunderland 2 injury when targeting peripheral nerves with cryoneurolysis is a critical component for clinical success and predictable outcomes.

When operators fall short of the desired uniform Sunderland grade 2 injury and the associated axonotmesis, the resulting nerve injury is called *neurapraxia* or Sunderland grade 1 injury (12,18,22). When it is compared with the desirable pain relief achieved with Sunderland grade 2 cryoneurolysis, Sunderland grade 1 injury temporarily manifests as favorable pain relief by means of temporary cessation of the conduction of pain signals, without axonal degeneration; however, this is then commonly followed by allodynia, in addition to worsening of preexisting symptoms and, possibly, new nerve-related undesirable symptoms. This syndrome is fortunately self limited.

On the other end of the spectrum of peripheral nerve injury is neurotmesis, or permanent nerve injury (Sunderland grades 3–5) (12,18,22,23). To our knowledge, there has been no report of permanent nerve damage during a cryoablation or cryoneurolysis procedure, which is likely related to the inability of current technology to remove the necessary energy to cause that severity of injury.

The clinical translation of these neuropathologic events is not always straightforward and likely accounts for the widespread difficulty in unifying the results in the literature (24). Most commonly, the nerve is underexposed during procedures secondary to one or several variables. Historically, dissemination of uniform protocols and outcomes has been limited by unknown in vivo temperature, improper cross-sectional area of coverage, adjacent blood flow, depth of the target area, nerve size and/or composition variability, and/or operator conservatism in the absence of established times and/or temperatures.

Table 1: Categorization of Nerve Injury with the Sunderland and Seddon Systems

Sunderland Grade	Seddon Description	Level of Neural Damage	Expected Recovery
1	Neurapraxia	Myelin sheath	Hours to weeks
2	Axonotmesis	Myelin sheath and axon	Weeks to months
3	Axonotmesis	Myelin sheath, axon, and endoneurium	Months
4	Axonotmesis	Myelin sheath, axon, endoneurium, and perineurium	Months to years
5	Neurotmesis	Myelin sheath, axon, endoneurium, perineurium, and epineurium	Months to years

Note.—When neurolysis is applied to create intentional nerve injury for therapeutic purposes, it creates the histopathologic outcomes expected with the application of heat, cold, and chemical neurolysis techniques.

Table 2: Cryoneurolysis Terminology

Nerve Block	Injection of Anesthetic with or without Steroids in a Neural Target
Diagnostic nerve block	Nerve block to a neural target of clinical suspicion to establish the sensory and motor outcome as a possible indication for neurolysis
Neurolysis	Destruction of a neural structure, which can be graded using the Sunderland categorization system
Cryoneurolysis	Destruction of a neural structure by exposing it to cold temperatures
Neuropraxia	A temporary block of nerve conduction due to injury; this is the Seddon terminology for a Sunderland category 1 nerve injury
Allodynia	Pain caused by a stimulus that is not normally painful
Hyperalgesia	Increased sensitivity to painful stimuli with an extreme response to stimuli that are normally painful
Phantom pain	Pain that the patient attributes to a limb that has been amputated

Furthermore, the absolute thermal energy imparted to the nerve during any procedure also depends on time, which is a notoriously poorly defined component of cryoneurolysis procedures.

Summary of Interventional Techniques

Cryoneurolysis can be performed on an inpatient or outpatient basis, usually with moderate sedation and local anesthesia, with a typical intraprocedural time of 90 minutes or less for a single intraprocedural target, including preparation, needle positioning, freeze-thaw cycles, and safe removal of the needle. Multiple targets may not prolong this time if they are accessed and frozen simultaneously. When CT is used, intermittent CT fluoroscopy approximately every few minutes or as desired by the operator can help to visualize the ice ball. Alternatively, superficial ice may be visualized with US to determine its distance from the skin and allow titration of the freezing power and application of skin-warming packs. US can be used to target superficial structures such as the distal sciatic nerve in the popliteal fossa, with the benefit of real-time Doppler US visualization for avoidance of vessels. However, targeting most structures in patients with an average or larger-than-average habitus likely requires CT guidance for optimal positioning. Furthermore, although US provides excellent real-time visualization of the proximity of the nondependent ice ball to the skin, it does not allow visualization of the deep margin of the ice, because the ice ball is sonopaque. Therefore, if deeper monitoring is necessary, CT is needed.

Specific to the freeze-thaw cycles, reported protocols for directed cryoneurolysis vary widely in the literature (14,24,25–30), from single cycles of 120 seconds to repeated cycles of 10 minutes, with intervening active or passive thawing. The primary limiting factor to establishing a consistent protocol is a technical limitation regarding the temperature throughout nerves of various sizes and compositions. A distinct energy function regarding temperature and time that results in the desired Sunderland 2 injury is affected by individual patient size, depth of target, size and composition of nerves, adjacent blood flow, cross-sectional area of the nerve involved in the ablation zone, and other factors. Current cryoablation devices are purely output devices, imparting cold with a consistent output that is

independent of in vivo variables that affect the final nerve function. As a result, operators are left to make educated guesses about the actual time necessary to achieve an unknown temperature at the target site for an optimal outcome. In addition, there does not appear to be a role for disruption of the osmotic gradient, as is the case for tumor destruction, obviating the need for an active thaw cycle during cryoneurolysis.

Related to these technical shortcomings are the most common adverse effects of cryoneurolysis, including allodynia, worsening of the underlying pain condition, and/or other unfavorable nerve-related sequelae, which result largely from neuropraxia induced by insufficient ablation (14,31,32). Likewise, nontarget ablation may result in muscle or adjacent organ destruction, increased pain, and increased risk of infection.

Access to Cryoneurolysis in the United States

Dissemination of cryoneurolysis in the United States has been limited by reimbursement issues. Historically available *Current Procedural Terminology* (CPT) codes for "destruction by a neurolytic agent (eg, chemical, thermal, electrical, or radiofrequency," CPT codes 64600–64681), which were nonspecific to cryoablation but specific to the targeted nerve, have been used. For example, CPT code 64620 is specific to destruction of an intercostal nerve but may be used for alcohol, radiofrequency, or other means of destruction, including cryoablation. Likewise, CPT code 64630 is specific to the pudendal nerve. As an indicator of values, facility payments for these two codes in 2022 were $175 and $193, respectively, which is inadequate to cover the costs of the procedure, even without advanced imaging guidance (33).

In October of 2015, the Centers for Medicare and Medicaid Services (CMS) approved three new category III CPT codes specifically for the cryoablation of nerves with advanced imaging guidance: *(a)* CPT code 0440T (ablation, percutaneous, and cryoablation; includes imaging guidance for upper extremity and distal peripheral nerves); *(b)* CPT code 0441T (ablation, percutaneous, and cryoablation; includes imaging guidance for lower-extremity and distal peripheral nerves); and *(c)* CPT code 0442T (ablation, percutaneous, and cryoablation; includes imaging guidance for the nerve plexus or other truncal nerves). These codes were subsequently extended in 2021 and valued by CMS to reflect appropriately the equipment and technology used by interventional radiologists. For example, the hospital outpatient and ambulatory rates of reimbursement set by CMS for CPT code 0442T in 2020 were $5509.01 and $3211.61, respectively, which are payments that allow advanced imaging guidance and the use of available cryoablation probes that are familiar to interventional radiologists (33–35).

Procedures

The interventional cryoneurolysis codes were specifically designed to account for imaging guidance and for broad categorization into one of three anatomic regions (ie, rather than a list of individual nerves), given the wide range of evolving targets and clinical applications. The examples described next illustrate the value and evolution of cryoneurolysis in interventional radiology. Many other applications and targets are possible and many likely remain to be discovered. The tools of cryoneurolysis are reviewed in Table 3, while Table 4 includes a comprehensive listing of the target neural structures in this report.

CPT Code 0442T

CPT code 0442T is for percutaneous ablation of a nerve plexus or truncal nerves.

Pudendal Nerves.—Cryoablation of the pudendal nerves exemplifies the principles of modern interventional cryoneurolysis and is a classic application from which other applications extend. The pudendal nerves are classic targets, because they meet the key considerations necessary for cryoneurolysis, including attention to the supply and composition of target nerves, diagnostic injection with cross-sectional imaging, advanced imaging guidance that allows ablation, neoplastic versus nonneoplastic cause of pain, percutaneously induced neuroregeneration, the potential to manage conditions other than pain, protocol considerations, and potential complications or adverse effects (7,13–15,36,37).

The paired pudendal nerves are the primary sensory nerves of the perineum, pelvic musculature, and external genitalia and provide minimal redundant motor function to the same areas (Fig 1). Each nerve arises from the anterior rami of the S2–S4 spinal nerves at the sacral plexus and courses along the internal pudendal artery and vein, wrapping around the sacrospinous ligament posteriorly to enter the pudendal canal. The pudendal canal is formed by the medial fascia of the obturator internus at the lateral margin of the ischiorectal fossa, which is easily identified on axial CT images. The inferior rectal nerve arises from the pudendal nerve proximally in the canal. The pudendal nerve then bifurcates near the distal (anterior) end of the canal, giving rise to the perineal nerve and the dorsal nerve of the penis or clitoris (38).

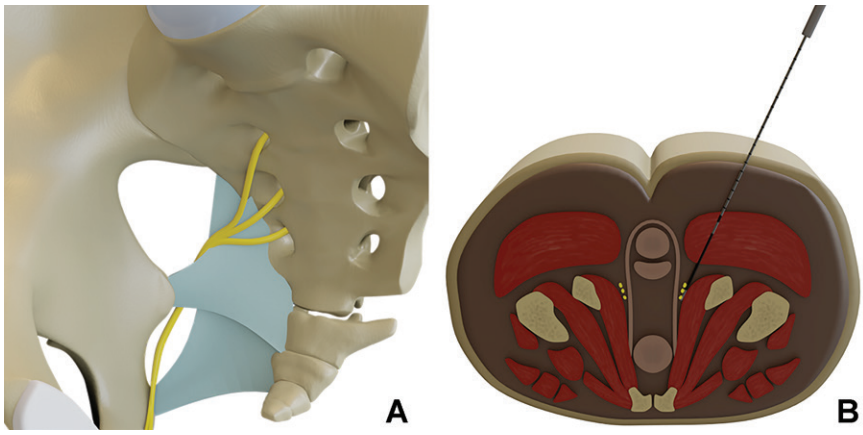

Figure 1. Illustrations show the pudendal nerve anatomy. **(A)** The pudendal nerve is created by contributions from the anterior rami of S2, S3, and S4 spinal nerves. **(B)** The pudendal nerve is targeted for cryoneurolysis at the level of the pudendal canal.

Table 3: Tools of Cryoneurolysis

Diagnostic nerve block	
22–25-gauge spinal or Chiba needle	Any needle size is suitable. Thicker needles hurt more but have improved steerability. The goal with all needles is to avoid lacerating the nerve.
Lidocaine with or without epinephrine, ropivacaine, or chloroprocaine	Lidocaine effect lasts 2 hours, and the duration improves to 6 hours with the addition of epinephrine. (Vasoconstriction increases lidocaine dwelling time by preventing reabsorption.) If available, ropivacaine (duration, 24–30 hours) is preferred by some operators. For patients with a lidocaine allergy, chloroprocaine can be considered.
Bupivacaine	Bupivacaine is longer acting (approximately 6 hours) than lidocaine and can be mixed with lidocaine, or lidocaine can be mixed with epinephrine.
M200 contrast material	Although any iodinated contrast material works well, M200 mixed at roughly a 1:10 contrast material to injectate concentration provides visualization of the injectate without causing streak artifact at CT, which limits visualization of the needle and adjacent critical structures.
Cryoneurolysis	
Cryoablation device	A variety of vendors have systems available; most currently use argon-based cooling systems. These systems require procurement of the argon gas with space in the procedure room for placement of these tanks.
Cryoablation probe (sizing based on vendor options for desired ice ball size)	CT-guided procedures benefit from 90° angled probe hubs, which allow alignment of the probe with the in-bore laser targeting system and also respect the limited space available in the gantry. Most probes freeze back from the tip, such that the tip should be inserted beyond the neural target to appropriately land the ice ball. Spherical ice ball shapes are almost always preferable to elongated ellipsoid shapes, which create a large ice tail that may need to be managed (eg, skin protection). Superficial targets benefit from shorter probe lengths (eg, 10-cm probe rather than a 17-cm probe).
Trocar needle, Gangi-HydroGuard (AprioMed) needle	A blunt-tip needle helps to navigate near the bowel and other sensitive structures without trauma, while landing the needle to allow infusion of fluids, air, or carbon dioxide to separate structures percutaneously and create space for safe formation of the ice ball.
Heat packs	If freezing targets are near the skin, heat packs should be applied. Sterile wrapping should be applied.
Decadron 10 mg intravenously on standby in case of undesired nerve injury	If an untoward nerve ablation occurs, an immediate neuroprotective dose of steroids reduces the severity of thermal neuritis and improves the chance of nerve recovery.

Pudendal neuralgia is a chronic pain disorder that is usually associated with trauma to the pelvis, most commonly, traumatic childbirth, gynecologic intervention, and/or bicycle or horseback riding injury (39). The diagnostic criteria for pudendal neuralgia include a positive response to a diagnostic block (ie, injection of bupivacaine deep to the obturator fascia, posterior to

Table 4: Summary of Cryoneurolysis Targets Reviewed

Neural Target	Example Clinical Vignette	Cryoprobe Position
Pudendal nerve	Perineal pain after traumatic childbirth	Pudendal canal at the ischiorectal fat pad
Ganglion impar	Perineal pain from pelvic tumor	Anterior to the sacrococcygeal ligament
Celiac plexus	Abdominal pain from pancreatic cancer	Juxta-aortic at the level of the celiac artery
Splanchnic nerves	Abdominal pain from pancreatic cancer	Juxta-vertebral at T11
Aorticorenal plexus	Flank pain from renal cell carcinoma	Juxta-arterial affected renal artery
Intercostal nerve	Chest pain from pathologic rib fracture	Immediately subcostal at the indicated rib level
Ilioinguinal and iliohypogastric	Inguinodynia after trauma	Medial to anterior superior iliac spine between the internal oblique and transversus abdominis muscles
Ilioinguinal and genitofemoral	Inguinodynia after herniorraphy	Anteromedial to the iliopsoas muscle at the level of the anterior inferior iliac spine
Vagus nerve	Obesity	Between the carina and gastroesophageal junction
Sciatic nerve	Tumor neuralgia	Deep to the gluteus at the level of the pelvis
Sciatic nerve after leg amputation	Stump allodynia	Popliteal fossa superior to the sciatic bifurcation
Obturator nerve	Acetabular metastasis with cancer neuralgia	Medial to the acetabulum at the midfemoral head level
Geniculate nerve	Osteoarthritis knee pain	Juxtaosseous metadiaphyseal junction of the femur and tibia
Sural nerve	Neuralgia after Achilles tendon repair	Posterior to the fibula above the ankle
Saphenous nerve	Neuralgia after vascular harvesting for coronary artery bypass graft	Medial knee adjacent to the saphenous vein
Lateral femoral cutaneous nerve	Postsurgical neuralgia	Anterior iliac bone at the level of the pelvis
Posterior femoral cutaneous nerve	Neuropathic pain	Posterior to the ischium in the pelvis
Peroneal nerve	Posttraumatic neuralgia	Posterolateral popliteal fossa
Brachial plexus	Malignant neuralgia	Inferolateral neck
Ulnar nerve	Posttraumatic neuralgia	Posterior to the ulna peripheral below the elbow

the inferior pubic ramus) of the pudendal nerve or nerves, in addition to pain in the appropriate distribution that is worsened by sitting, does not wake the patient up at night, and is not accompanied by objective sensory loss (40). The ability to directly confirm expansion of the pudendal canal with injectate at CT is an invaluable diagnostic tool in patients suspected of having pudendal neuralgia, because it serves as a concrete "crossroads" that guides future therapy. That is, if patients do not respond to an injection performed with landmark or fluoroscopic guidance, pudendal neuralgia must remain in the differential diagnosis because of the possibility that the injection missed its mark. At CT, pudendal neuralgia may be ruled out in patients who do not respond to a confirmed injection, allowing efficient continued diagnostic work on behalf of the patient. On the other hand, response to a confirmed injection is selective for patients who are likely to benefit from directed therapy (Fig 2A).

Likewise, CT guidance allows safe and precise targeting of the pudendal nerve in the pudendal canal. Adjacent deep pelvic viscera may be avoided and the pudendal nerve(s) may be confidently ablated (Fig 2B). Other methods of targeting the pudendal nerve percutaneously (eg, landmark, fluoroscopic, transvaginal, nerve stimulator, or other targeting methods) are substantially more difficult, more dangerous, and less precise, such that ablative technologies are typically not offered. Surgical approaches carry increased cost, morbidity, and associated recurrence related to adhesions that developed because of the surgery itself. Also,

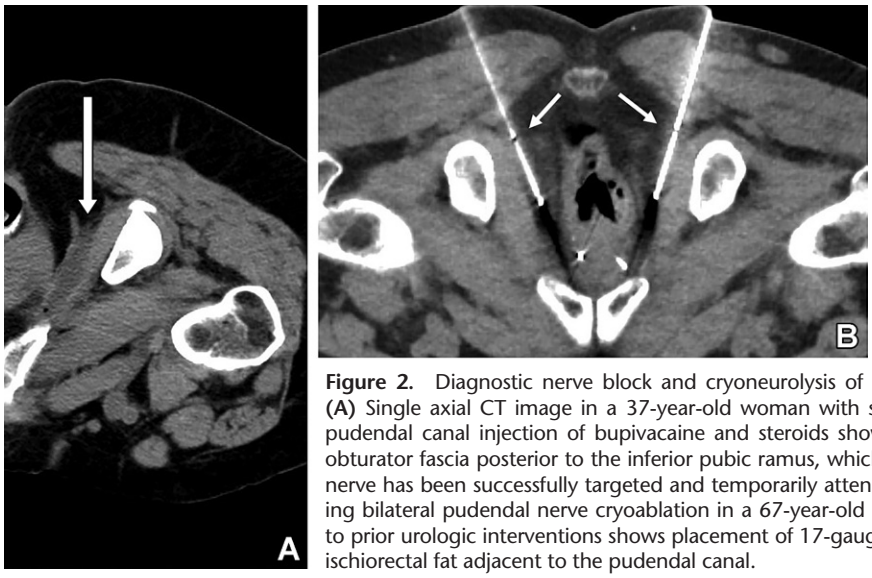

Figure 2. Diagnostic nerve block and cryoneurolysis of the pudendal nerve in two patients. **(A)** Single axial CT image in a 37-year-old woman with suspected pudendal neuralgia after a pudendal canal injection of bupivacaine and steroids shows fluid and air (arrow) deep to the obturator fascia posterior to the inferior pubic ramus, which is a confirmation that the pudendal nerve has been successfully targeted and temporarily attenuated. **(B)** Single axial CT image during bilateral pudendal nerve cryoablation in a 67-year-old man with pudendal neuralgia related to prior urologic interventions shows placement of 17-gauge cryoablation probes (arrows) in the ischiorectal fat adjacent to the pudendal canal.

neuromodulation involves a permanently implanted device (41).

In addition to illustrating the value of advanced imaging guidance, diagnostic blocks, and the importance of considering the distribution and composition of targeted nerves, the pudendal nerves also serve as an example target for the management of cancer-related pain (42). In patients with pain related to a neoplasm, interventional radiologists who identify the transmitting nerve from the offending mass are likely to have the skills and technology to reach that nerve percutaneously and block the pain signal safely with cryoablation. In the case of pelvic masses, the pudendal nerves represent pain-transmitting structures with minimal motor or visceral control, such that intractable pain related to pelvic masses may be improved with percutaneous CT-guided cryoablation of the bilateral pudendal nerves (7,42). That said, as we mentioned in the description of nerve composition and anatomy of the pudendal nerves, the pelvic nerve supply is complex, redundant, and overlapping. Pudendal nerve cryoablation in this setting may be viable for palliation in isolation or in combination with other targets such as the superior or inferior hypogastric plexi, pelvic splanchnic nerves, or uterosacral nerves (43).

Pudendal nerve cryoneurolysis in patients with pudendal neuralgia is also a clinical example of the benefit of neuroregeneration after the application of cold. Given that patients with pudendal neuralgia often have underlying nerve injury, they may benefit from induced neuroregeneration after a deliberate Sunderland 2 injury, because the resulting regenerated axons were not present during the original injury (13–15,36,44).

Cessation of conduction and/or induction of neuroregeneration with cryoneurolysis may also be considered in patients with nonpain syndromes. For example, premature ejaculation is the most common sexual disorder in men worldwide, with more than 45 million men with the diagnosis in the United States alone and up to 50% of men affected worldwide (45,46). A pilot trial (37) targeting the dorsal penile nerve (a branch of the pudendal nerve) with cryoneurolysis under CT guidance showed technical feasibility and improved outcomes in a small group of men with premature ejaculation. Going forward, pudendal nerves may be a more appropriate target in these patients, given the improved understanding of distal degeneration from the ablation site (12,13,36).

Interventional cryoneurolysis also may be useful for myriad nerve-mediated clinical conditions that are not pain related. In the case of the pudendal nerves, operators must take care to avoid nontarget ablation of medial structures such as the rectum, prostate, or vagina, given the consistent ovoid shape of available ablation zones. Also, undesirable damage to the mechanical nerves may result from penetration of the nerve with the cryoablation needle itself. The goal of the procedure is to decrease the temperature throughout the nerve by extending a region of cold across the target. Operators should take care not to contact the nerve directly with the needle. For pudendal nerves, orienting the probe adjacent to the nerve in the ischiorectal fat provides an effective location from which to extend an ablation zone without piercing the nerve itself (Fig 2B).

Ganglion Impar.—As a visceral counterpart to the somatic pudendal nerves, the ganglion impar can carry pain derived from pelvic abnormalities. This structure is located atop the coccyx around the sacrococcygeal ligament. Response to a

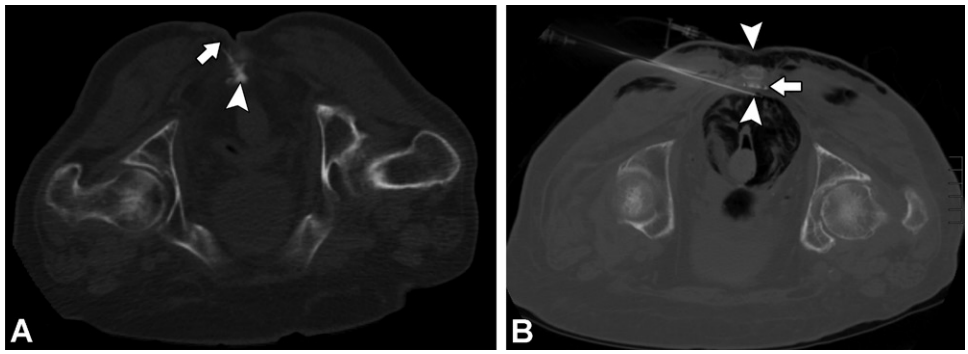

Figure 3. Recurrent squamous cell carcinoma of the vulva in an 80-year-old woman with intractable cancer-associated pain despite undergoing 66-Gy radiation therapy and ongoing systemic chemotherapy (carboplatin and paclitaxel). Pain-directed intervention that would not interrupt ongoing chemotherapy was requested. After several months of complete pain relief from pudendal cryoneurolysis, the patient had tumor progression with increased deep pelvic pain. Subsequently, a ganglion impar diagnostic nerve block was performed. **(A)** Axial intraprocedural CT image with the patient in a prone position shows a 25-gauge needle (arrow) with the tip anterior to the sacrococcygeal ligament, injecting lidocaine with epinephrine mixed with M200 contrast material (5:1 ratio) (arrowhead). The patient noted complete pain relief while she was still on the table. Pain relief achieved at diagnostic nerve block was subsequently consolidated with cryoneurolysis of the ganglion impar. **(B)** Axial intraprocedural CT image shows a 17-gauge cryoprobe (arrow) placed anterior to the sacrococcygeal ligament. Additional needles (arrowheads) have been placed in the pararectal and subcutaneous spaces to infuse room air for insulative pneumoprotection of the rectum and dermis, respectively, from cryoinjury.

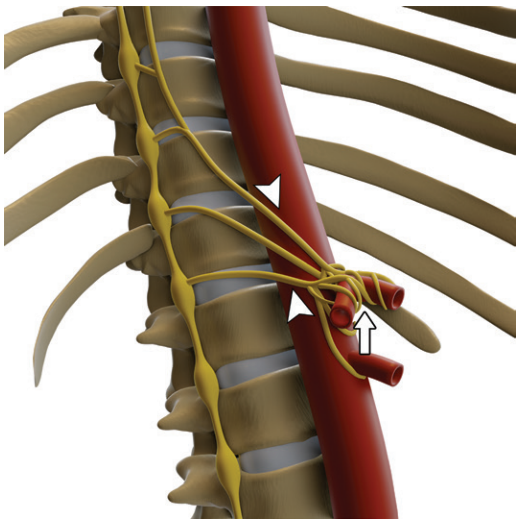

Figure 4. Illustration shows the celiac plexus fibers encasing the celiac artery (arrow) and proceeding cranially as the visceral splanchnic fibers (between arrowheads).

diagnostic nerve block at this level (typically with the needle at the sacrococcygeal ligament) can be consolidated with cryoneurolysis of the ganglion. Cryoneurolysis (25) avoids the risk of a liquid neurolytic in this relatively confined space. The main risk is the nontarget spreading of neurolytic agent to injure the ventral sacral nerve roots (ie, S1 and S2). Procedural consideration should be given to unintentional injury of the rectum and the skin on the other side of the coccyx, for which hydrodissection and/or pneumodissection can be considered for visceral and dermoprotection (Fig 3).

Celiac Plexus and Splanchnic Nerves.—The celiac plexus is a retroperitoneal confluence of neural input from visceral ganglia (ie, the aorticorenal, superior mesenteric, and celiac ganglia), which exist as an axonal meshwork that drapes around the abdominal aorta cranially through the aortic hiatus of the diaphragm, at which point this same neural supply continues as the visceral splanchnic fibers traveling along the vertebral bodies (Fig 4). Clinically, the celiac plexus provides a reasonable interventional target for intractable pain arising from the upper abdominal viscera (ie, classically abdominal neoplasia). The cryoneurolytic approach to this target has been shown to have fewer gastrointestinal adverse effects (26) and is especially helpful in cases where scarring may limit the spreading of a liquid neurolytic agent (eg, prior ethanol neurolysis or radiation therapy, or direct tumor adhesions) and in cases where local control of a directly invading tumor may improve durability of the local therapy (Fig 5). Procedural consideration should be given to inadvertent ablation of the adrenal glands, which can result in a hypertensive crisis at the first thaw (27).

The greater, lesser, and least splanchnic nerves are paired autonomic nerves that carry nociceptive stimuli from the celiac plexus and aorticorenal plexus to the spinal cord and, therefore, provide an alternative target for intervention, with a broader area of pain relief compared with therapy directed to the celiac plexus (Fig 6). The splanchnic nerves can be targeted along the lateral and anterolateral margins of the lower thoracic vertebral bodies, most commonly at the T11 and/or T12 levels (28). Splanchnic neurolysis and ablation have been shown to be effective in treating pain from pancreatic cancer, even in patients who did not respond to neurolysis of the celiac plexus (29–31). Cryoablation is especially preferable to ethanol neurolysis at this site, given the proximity to somatic nerve roots, the spinal cord, and the artery of Adamkiewicz.

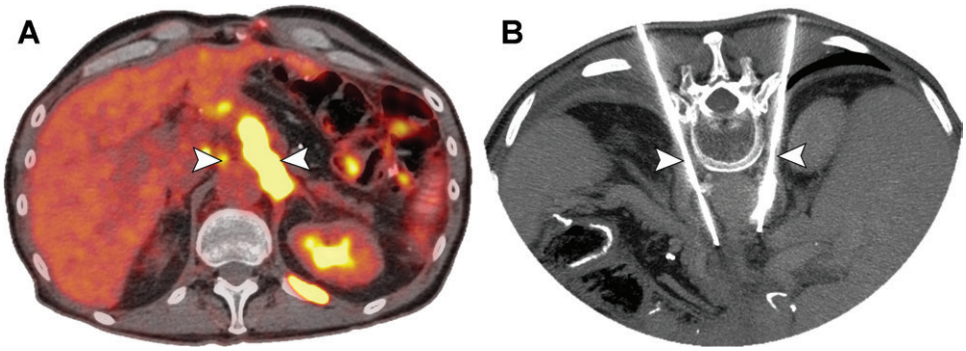

Figure 5. Chemotherapy- and radiation therapy–resistant metastatic esophageal adenocarcinoma in a 63-year-old man with epigastric pain radiating to the back who was not able to tolerate opioids and was experiencing intractable pain. Focal pain-directed therapy was desired that would allow continuation of his current fourth-line systemic therapy and maintain his eligibility for a clinical trial in the near future. **(A)** Axial PET/CT image shows hypermetabolic tumor deposits along the anterior aorta at the level of the celiac artery, greater on the left than on the right (arrowheads). Tumor invasion was believed to be preventing adequate spread of the liquid injectate; therefore, primary cryoneurolysis of the celiac plexus was planned. **(B)** Axial intraprocedural CT image with the patient in a prone position shows cryoprobes (arrowheads) bracketing the aorta at the level of the celiac artery.

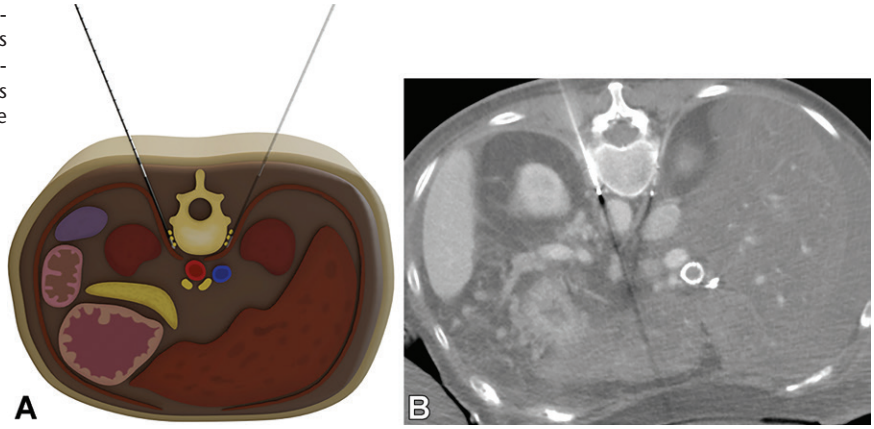

Figure 6. Visceral splanchnic cryoneurolysis. **(A)** Illustration shows cryoprobe placement. **(B)** Axial intraprocedural CT image with intravenous contrast material shows the same placement of cryoprobes.

Aorticorenal Plexus.—The neuronal meshwork draping over the renal artery serves as the renal plexus, culminating in the right and left aorticorenal ganglia before ascending to join fibers of the celiac plexus. Having gained some attention in hypertensive therapeutics through sympathectomy, this plexus can carry flank pain from benign (32) and malignant (47) conditions. Procedural consideration should be given to placing cryoprobes above and below the renal artery (Fig 7) to achieve circumferential cryoneurolysis.

Intercostal Nerve.—The intercostal nerves carry dermatomal pain signals to the dorsal root ganglion and then to the spinal cord. These nerves were the subject of some of the earliest trials of cryoneurolysis, and there is continued interest in targeting these nerves for the reduction of pain after thoracotomy, the Nuss procedure for repair of pectus excavatum, and surgical stabilization of rib fractures. The nerves can be targeted percutaneously with imaging guidance or intraoperatively with direct visualization or nerve-stimulator guidance (Fig 8). The results are especially promising, given the potential for a reduced requirement for administration of narcotic drugs (48–50). In a 2020 retrospective study (51) of CT-guided cryoneurolysis of the thoracic nerve roots for the relief of neuropathic pain in the chest wall, the authors reported positive results. The median duration of pain relief was 45 days, and there were no major complications. Postprocedural anticipatory guidance may be given to subtle bulges in the abdominal wall that can develop because of denervation of the motor fibers that also travel in the intercostal nerve.

Ilioinguinal, Iliohypogastric, and Genitofemoral Nerves.—Inguinodynia, or pain in the inguinal region (ie, the hemiscrotum, the adjacent anteromedial groin, and the immediate suprapubic skin), correlates to known sensory innervation. This innervation is via the iliohypogastric, ilioinguinal, and genitofemoral nerves. Although postherniorraphy impingement is a common cause, sporadic cases are seen as well. Procedural consideration should be given to cryoneurolysis at one of two positions based on pain distribution.

One treatment location to consider for inguinodynia is the confluence of the iliohypogastric and

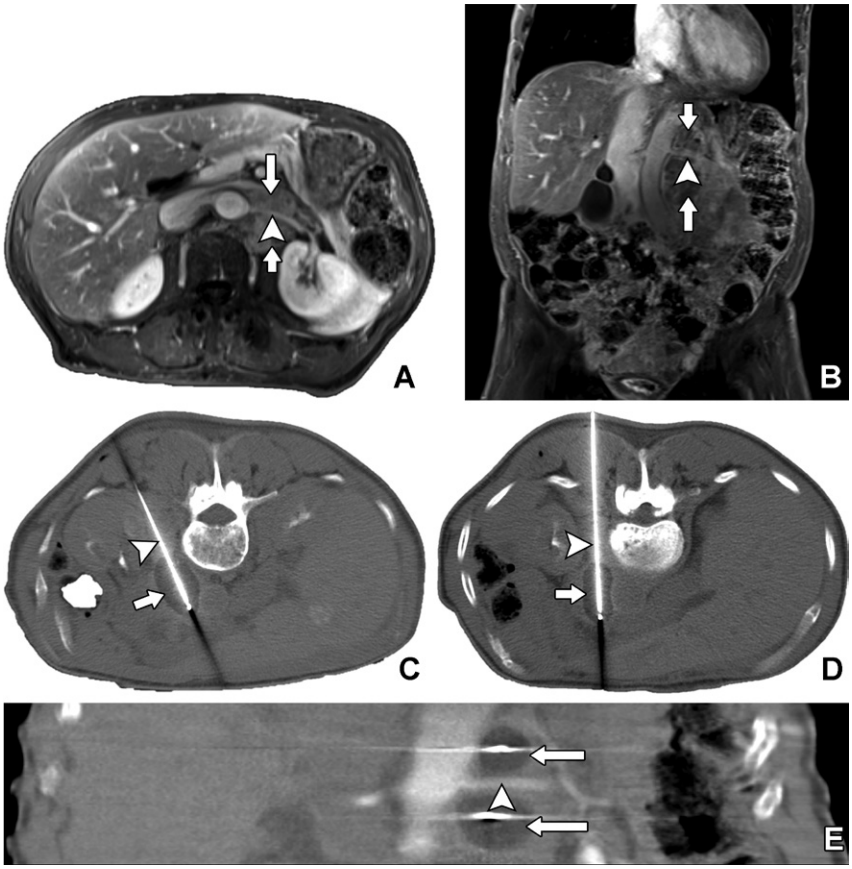

Figure 7. Intractable left flank pain from a neuroendocrine tumor in a 72-year-old man that was unresponsive to 30-Gy radiation therapy. The patient reported an average pain level of nine on a scale of 10, despite taking 2 mg of hydromorphone every 4 hours and 30 mg of extended-release morphine twice daily, acetaminophen, and naproxen. Pain-directed focal therapy that would not interrupt ongoing systemic treatment (everolimus) was requested. **(A, B)** Axial **(A)** and coronal **(B)** contrast-enhanced T1-weighted MR images show the tumor (arrows) encasing the left renal artery (arrowhead), precluding the spread of a liquid block; therefore primary cryoneurolysis was planned. **(C, D)** Axial intraprocedural CT images with the patient in a prone position show the placement of the cryoprobe (arrowhead) and ice (arrow) superior **(C)** and inferior **(D)** to the renal artery. **(E)** Coronal reconstructed intraprocedural CT arteriogram shows ice growth superior and inferior (arrows) to the renal artery (arrowhead).

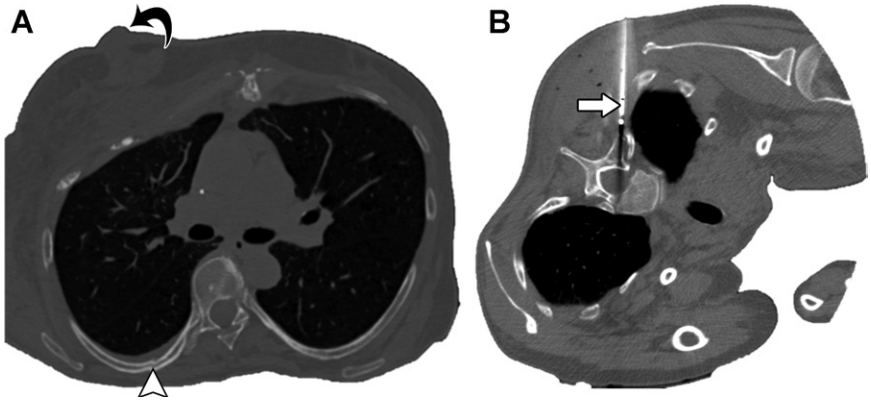

Figure 8. Estrogen- and progesterone-receptor–negative, human epidermal growth factor receptor 2–amplified metastatic breast cancer in a 58-year-old woman with crescendo somatic breast pain secondary to a locally recurrent right breast mass that was ulcerating through her skin, a postradiation therapy right rib fracture, nonunion and crescendo neuropathic intercostal pain and allodynia, substantial pain with change of breast dressing, and pain when lying on her back so that she was only able to sleep in the left-side-down decubitus position. She was receiving active fourth-line systemic therapy (fam-trastuzumab deruxtecan) and had a strong desire to not delay systemic therapy for concern of losing efficacy. Pain persisted in spite of administration of 40 mg of methadone and 16–24 mg of hydromorphone every 3 hours, in addition to propranolol, duloxetine, and nortriptylene. **(A)** Axial preprocedural CT image shows an ulcerative breast mass (arrow) and rib fracture with nonunion (arrowhead). An intercostal nerve block at this index level and one level above and below provided pain relief, which was consolidated with intercostal cryoneurolysis at these same levels. **(B)** Axial intraprocedural CT image with the patient in the decubitus position shows the cryoprobe (arrow) in the subcostal space as cryoablation was performed cranial and caudal to the index level. Systemic therapy was not delayed.

ilioinguinal nerves (ie, the iliohypogastric ilioinguinal confluence). This occurs medial to the anterior superior iliac spine between the internal oblique and transversus abdominis muscles (Fig 9).

The other treatment location to consider for inguinodynia is the confluence of the ilioinguinal and genitofemoral nerves (ie, the ilioinguinal genitofemoral confluence). This occurs anteromedial to the iliopsoas muscle at the level of the anterior inferior iliac spine.

Vagus Nerve.—Interruption of the vagus nerve results in decreased appetite and attenuation of weight gain, and/or weight loss in all species

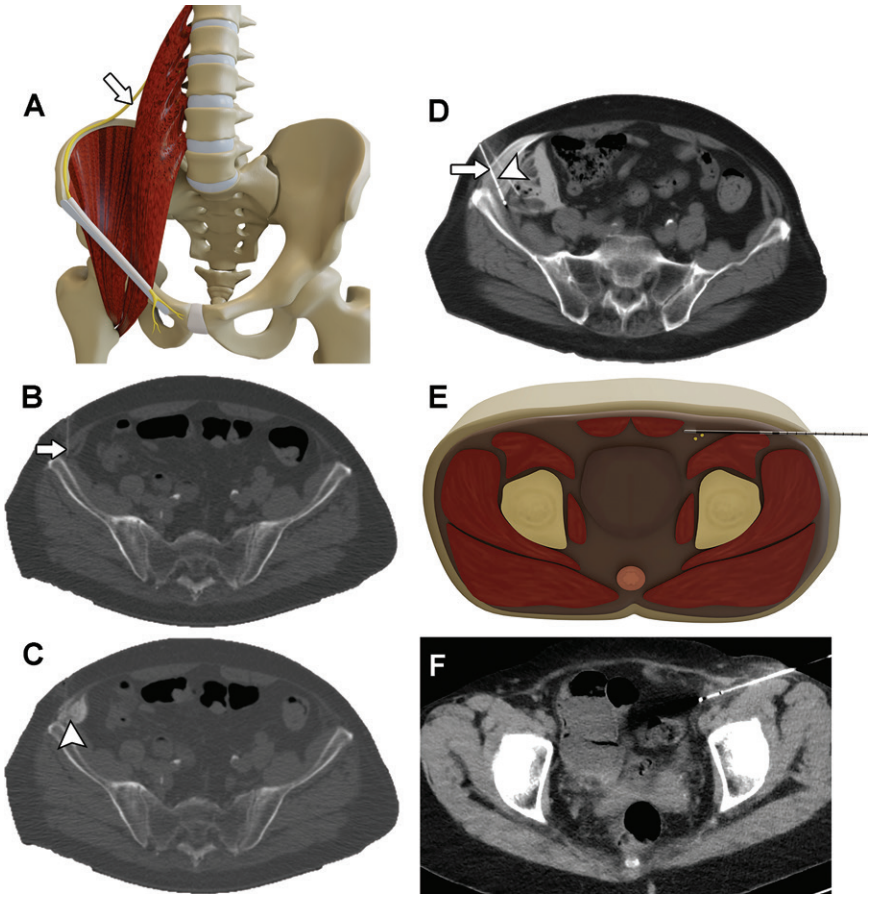

Figure 9. Cryoneurolysis approaches to inguinodynia in a 70-year-old man with sporadic right inguinodynia. The neuropathic pain pattern involved the distribution of the ilioinguinal and iliohypogastric nerves around the inguinal region, but not the distribution of the genitofemoral nerve. **(A)** Illustration shows the anatomic course of the ilioinguinal nerve (arrow). **(B)** Axial intraprocedural CT image shows a 25-gauge needle (arrow) with the tip in the interfascial plane between the internal oblique and transversus abdominis (ie, the iliohypogastric-ilioinguinal confluence treatment position). **(C)** Axial intraprocedural CT image shows that the mixture of lidocaine and contrast material (5:1 ratio) (arrowhead) has been injected to yield complete pain relief. **(D)** Axial intraprocedural CT image shows the cryoprobe (arrow) placed at the ilioinguinal-iliohypogastric confluence, and that the needle is placed medially (arrowhead) to provide protective hydrodissection fluid mixed with iodinated contrast material to push the colon away from the cryozone. **(E)** Illustration shows the cryoneurolytic approach to the ilioinguinal-genitofemoral confluence treatment position for inguinodynia. **(F)** Axial intraprocedural CT image shows the cryoprobe placed at the same treatment position as that in **E**.

studied to date (52). Prologo et al (53) designed a safety and feasibility evaluation of percutaneous CT-guided cryoablation of the posterior vagal trunk in patients with mild to moderate obesity (body mass index, 30–37 kg/m^2) (53). The posterior vagal trunk is targeted between the carina and gastroesophageal junction as it courses posterolaterally along the esophagus (Fig 10). There were no procedure-related complications or adverse events during the 6-month follow-up period of the pilot trial, and subjects lost an average of 5.6% of total body weight, with 22.7% of excess body mass index lost (change in body mass index/[initial body mass index– 25]). Participants reported decreases in appetite after the procedure at all time points, with 15.8% reporting "somewhat less appetite," 68.4% reporting "much less appetite," and 10.5% reporting "very much less appetite" (53,54). Procedural safety regarding the esophagus involves two factors. First, the nearby aorta provides abundant warming for nearby structures. Second, the probe is purposefully pointed at the structure that is to be protected, because current cryoprobes have a reliably minimal "forward-freezing" capability (ie, ice grows radially behind the tip of the probe without substantial extension beyond the tip).

Brachial Plexus Nerve Bundle.—The brachial plexus is the largest nerve bundle in the body. It comprises all the motor and sensory fibers for the upper extremity. The brachial plexus provides a technical challenge to balancing motor sacrifice, establishing uniform cold, and safely navigating nearby vascular and neural structures. Direct involvement with metastatic disease or intractable pain related to masses involving the upper extremity that are associated with motor loss presents opportunities to target this plexus (Fig 11).

CPT Code 0441T

CPT code 00441T is for percutaneous ablation of lower extremity distal and peripheral nerves.

Sciatic Nerve.—The sciatic nerve is the largest nerve in the human body, carrying motor and sensation to the lower extremity. Cryoneurolysis of the sciatic nerve is most commonly appropriate in patients with neoplastic disease, which is associated with motor loss that is refractory to other interventions. Phantom or residual limb

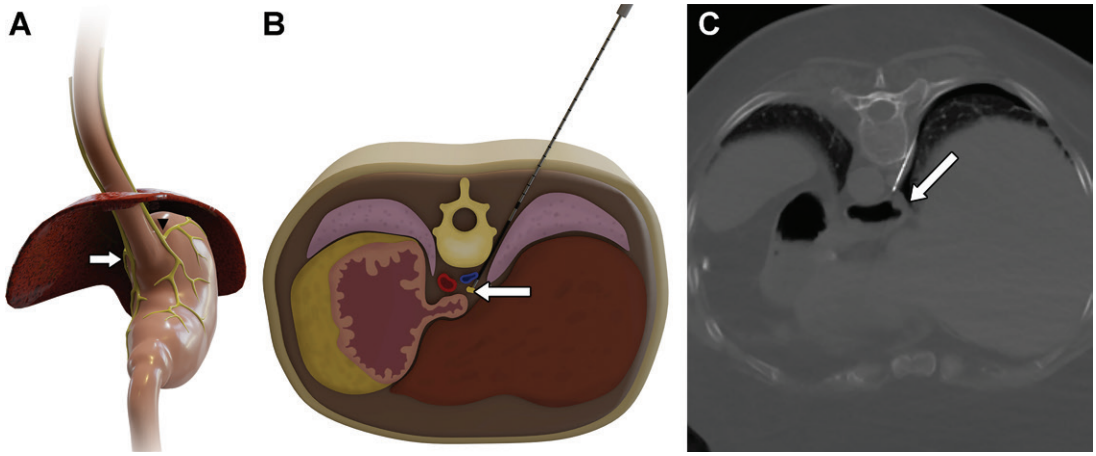

Figure 10. Vagal nerve cryoneurolysis. **(A)** Illustration shows the anterior gastric nerves (arrowhead) and posterior vagal trunk (arrow). **(B)** Illustration shows the cryoneurolytic approach to the posterior vagal trunk (arrow). **(C)** Axial intraprocedural CT image shows placement of a cryoablation probe during a vagal nerve cryoneurolysis procedure in a 47-year-old woman with class II obesity, targeting the known course of the posterior vagal trunk posterolaterally along the esophagus (arrow).

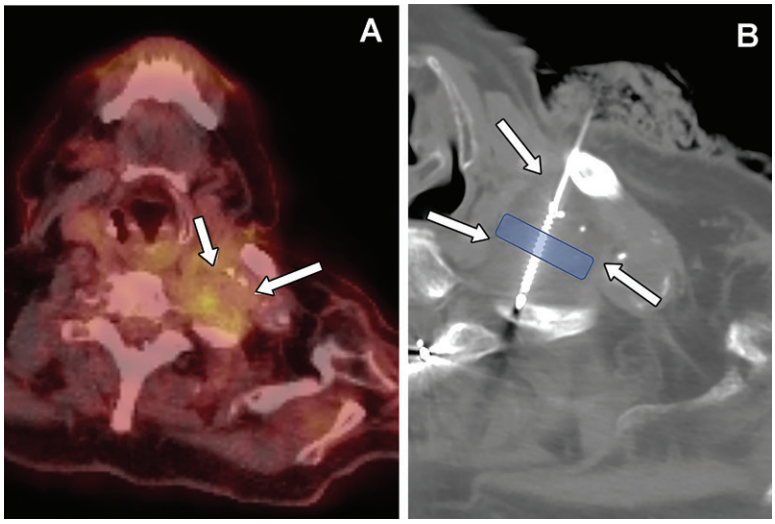

Figure 11. Known metastatic sarcoma and intractable left upper extremity pain with associated motor loss in a 70-year-old man. **(A)** Axial fused PET/CT image shows a mass involving the brachial plexus (arrows). **(B)** Corresponding intraprocedural CT image shows a large ablation zone (arrows) engulfing the mass and the brachial plexus interface (blue rectangle).

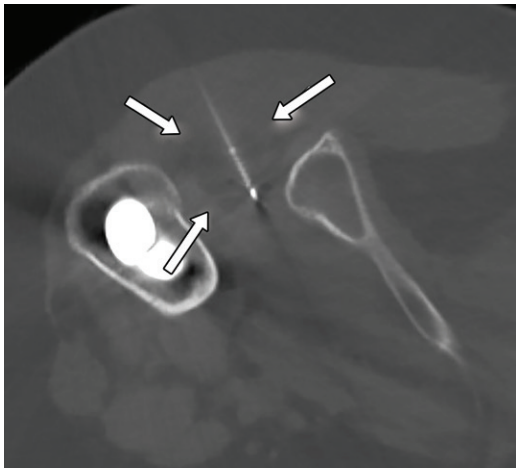

Figure 12. Single axial intraprocedural CT image shows the ablation zone (arrows) during a sciatic nerve cryoneurolysis procedure, targeting the known course of the sciatic nerve deep to the gluteal musculature in the pelvis in a 57-year-old woman with metastatic sarcoma, intractable pain, and associated motor weakness in the sciatic distribution.

pain is also a common indication for sciatic cryoneurolysis (55,56) The nerve is targeted depending on the underlying lesion either proximally in the pelvis (Fig 12) or distally above its bifurcation in the popliteal fossa.

Variably coexisting stump allodynia and phantom limb pain can arise after transfemoral amputation (sciatic nerve) or transtibial amputation (tibial nerve). If imaging does not reveal a neuroma, which is the primary target for cryoablation, the nerve corresponding to the reported pain distribution can be approached for neurolysis (55). Sometimes skin from one territory can be oversewn to create a stump that appears to overlap with a different territory, and diagnostic nerve blocks can be helpful to confirm the anticipated response to cryoneurolysis. Simultaneous cryoneurolysis of an accessible portion of the distal sciatic nerve may be undertaken with cryoneurolysis of the fibular nerve, which may arise from the sciatic nerve more cranially (Fig 13).

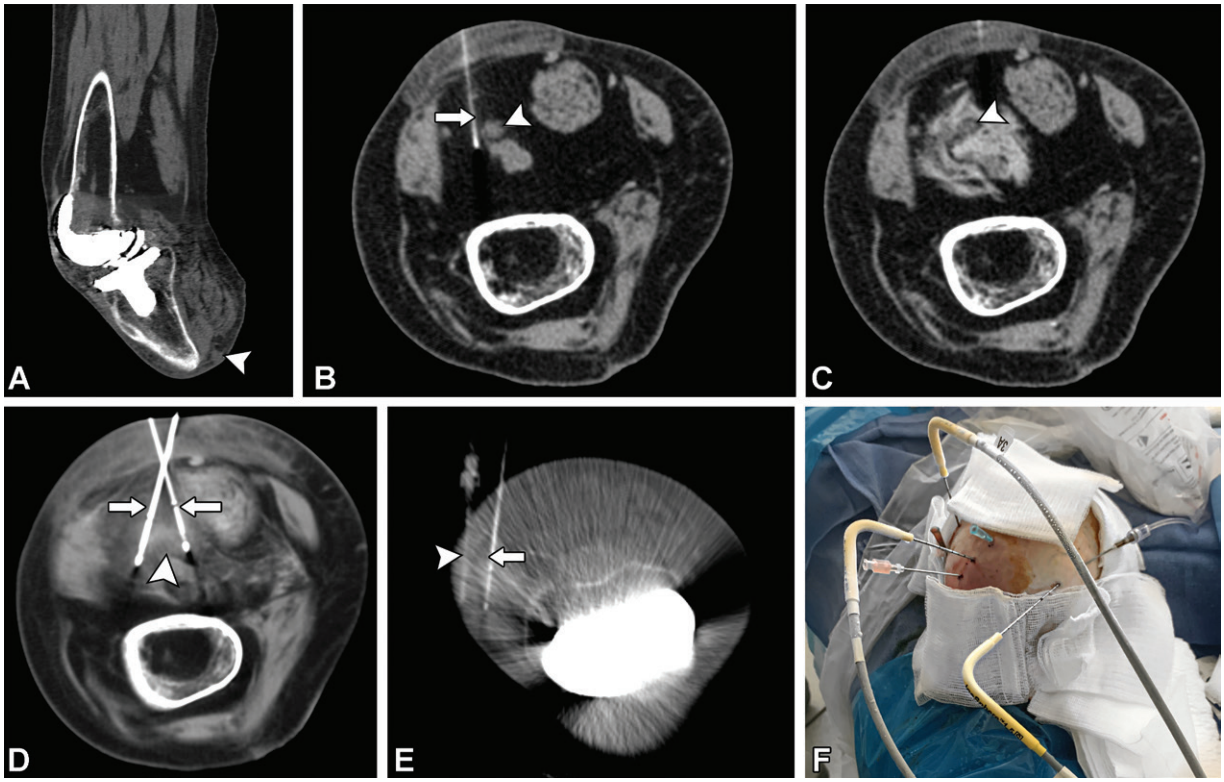

Figure 13. Cryoneurolysis procedure targeting the nerve distally at the level of the popliteal fossa in a 60-year-old man with a history of leg amputation below the knee for nonhealing ulcers of venous insufficiency, total knee arthroplasty for arthritis performed 10 years later, and a left lateral tibial neuroma that was surgically resected and removed but recurred. The neuroma was limiting his ability to wear his prosthesis, and he had phantom pain in both the tibial and fibular nerve distributions. He refused repeat resection, was currently undergoing anticoagulation therapy, and desired to avoid converting to above-knee amputation because of his acclimation to the prosthetic. **(A)** Sagittal preprocedural CT image shows a neuroma (arrowhead) that is inseparable from the skin. Neuroma cryoablation was originally planned, but when the patient was under general anesthesia, initial attempts at hydrodissection from the skin flap were only partially successful. To ensure maximum pain relief, combined distal sciatic nerve and fibular nerve cryoneurolysis was planned. **(B)** Axial intraprocedural CT image shows the needle (arrow) adjacent the distal sciatic nerve (arrowhead). **(C)** Axial intraprocedural CT image shows contrast material–laden nerve block fluid injected around the distal sciatic nerve (arrowhead). **(D)** Axial intraprocedural CT image shows paired cryoprobes (arrows) bracketing the distal sciatic nerve (arrowhead). **(E)** Axial intraprocedural CT image shows the cryoprobe (arrow) lateral to the fibular head in the treatment position for the fibular nerve. An additional needle (arrowhead) lateral to the cryoprobe instills hydrodissection fluid to push away the dermis from the cryozone, protecting it from cryoinjury. **(F)** Intraoperative photograph with the patient in a prone position shows the geometry of cryoprobes and hydrodissection needles at one point in neuroma cryoablation, plus sciatic and fibular cryoneurolyses for amputation stump phantom pain and prosthetic pain.

Obturator Nerve.—Isolated pain occurring along the medial superior thigh should prompt an investigation for the cause along the course of the obturator nerve, which is reliably located medial to the acetabulum and the level of the midfemoral head. Adductor innervation prevents a sideward "strafing gait," which should be included in the informed consent for obturator nerve interventions because it may increase the risk of a fall. Cryoneurolysis of the expected nerve location can be performed to provide relief from cancer pain (Fig 14).

Geniculate Nerves.—Patients with osteoarthritic knee pain who have not found relief from in-office injections but are not yet candidates for total knee arthroplasty may benefit from either genicular artery embolization (57) or denervation therapy such as radiofrequency ablation or cryoneurolysis (55). Of the up to 11 nerves serving the knee capsule (58), five have consistent locations predicted by anatomic landmarks (59) and three (the superior lateral, superior medial, and inferior medial geniculate nerves) are commonly treated synchronously (Fig 15). The inferior lateral geniculate nerve is traditionally avoided because of its proximity to the fibular nerve; however, if the patient has point tenderness in the inferior lateral knee, CT guidance allows safe targeting of the nerve on the Gerdy tubercle (Fig 16). In randomized controlled trials of geniculate cryoneurolysis, Nygaard and colleagues (60) and Mihalko et al (61) provided level 1 data that preoperative geniculate cryoneurolysis improves postarthroplasty pain outcomes.

Sural Nerve.—The sural nerve is a predominately sensory nerve supplying the lateral leg, lateral

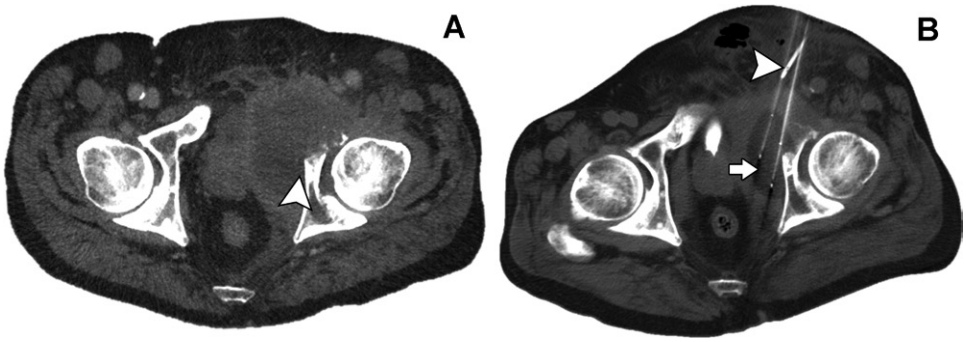

Figure 14. Metastatic non–small cell lung cancer in a 59-year-old man who presented with crescendo pain with neuropathic pain (ie, constant, burning, and sharp) in the left obturator nerve distribution (ie, left medial thigh). Pain crescendo was occurring despite 37.5-Gy radiation therapy, 60 mg of oxycodone every 8 hours, plus 20–40 mg of breakthrough oxycodone every 3 hours, in addition to amitriptyline, tizanidine, dronabinol, and dexamethasone. Tumor encasement precluded liquid spreading to allow a diagnostic nerve block. The desire was to not interrupt ongoing systemic therapy (alectinib), and the patient did not want an intrathecal drug delivery device, so primary cryoneurolysis of the obturator nerve was planned. **(A)** Axial preprocedural CT image shows tumor infiltration of the expected area of the obturator nerve, medial to the acetabulum at the midfemoral head level (arrowhead). **(B)** Axial intraprocedural CT image shows ice coverage emanating from paired cryoprobes (arrow) to treat the obturator nerve and a hydrodissection catheter (arrowhead) to push the spermatic cord medially with isoattenuating hydrodissection fluid to create space for safe entry of the cryoprobe medial to the femoral vessels.

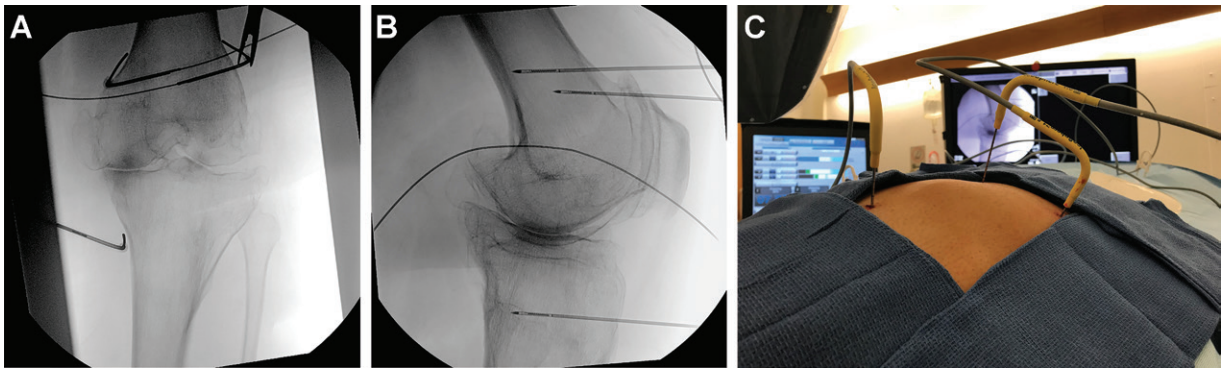

Figure 15. Bilateral Kellgren-Lawrence grade 4 osteoarthritis in a 50-year-old woman who tried in-clinic injections without success and was not a surgical candidate for total knee arthroplasty. She previously underwent geniculate nerve radiofrequency ablation neurotomy of the contralateral knee but was unable to tolerate heat-based ablation in spite of local anesthesia, geniculate nerve blocks, and sedation. After a successful diagnostic geniculate nerve block was performed, geniculate nerve cryoneurolysis was planned for the remaining knee. **(A)** Frontal radiograph shows the landmark technique for the placement of cryoprobes at the metaphyseal shaft junction of the femur medially and laterally (superior medial and superior lateral geniculate nerves, respectively) and the tibia (inferior medial geniculate nerve). **(B)** Lateral radiograph reveals the landmark technique with the cryoprobe depth past the midshaft depth. **(C)** Photograph shows the probe geometry during geniculate nerve cryoneurolysis. The patient's postprocedural Western Ontario and McMaster Universities Osteoarthritis Index score decreased from 88 to 36 (of the highest possible score, 96), and the patient experienced restored ambulation for activities of daily living at just 2 weeks after cryoneurolysis.

ankle, and dorsum of the foot. It is particularly vulnerable to injury during trauma (specifically, calcaneal fracture) or surgery (specifically, Achilles tendon repair) (62). The resulting neuropathic syndrome may be treated by specifically targeting the sural nerve as it courses posterior to the fibula above the ankle (Fig 17). Because the mechanism of injury is trauma and development of lower peripheral nerve thresholds and higher excitability (63), patients with sural nerve injury are excellent candidates for induced wallerian degeneration, with subsequent axonal regeneration and potential cure (10,36,64).

Saphenous Nerve.—Similarly, the saphenous nerve is vulnerable to iatrogenic damage during vascular harvesting procedures or orthopedic procedures and carries sensation primarily from the lower leg. Saphenous nerve cryoablation has also been described (7) for the management of painful peripheral extrinsic disease involving the lower leg, such as metastatic disease. The saphenous nerve may be safely targeted as it courses with the saphenous vein along the medial side of the knee (Fig 18). Radnovich and colleagues (65) performed a multicenter, randomized, double-blind, sham-controlled trial that demonstrated significant improvement of pain.

Femoral Cutaneous Nerves.—The lateral femoral cutaneous nerve (Fig 19A) has been targeted with cryoneurolysis to provide long-acting analgesia in patients with skin grafts for management of pain related to burns, and in patients

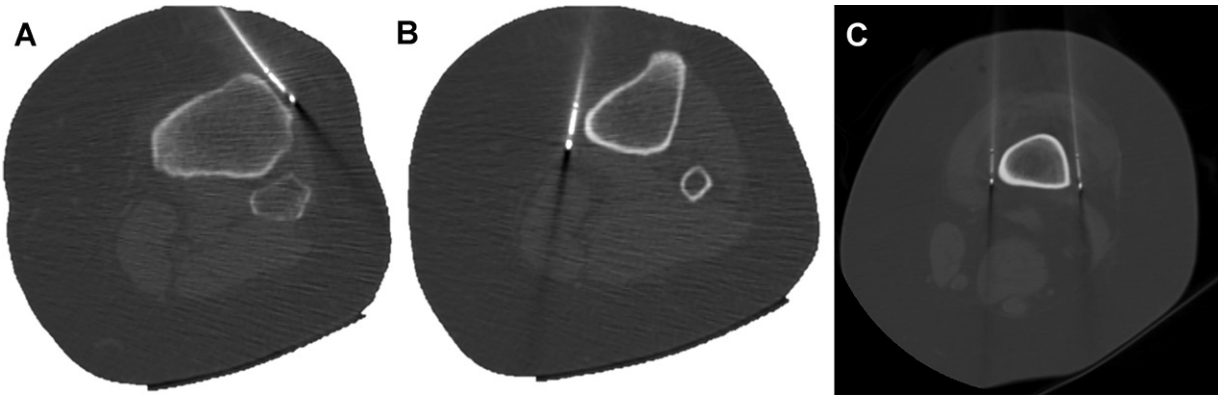

Figure 16. Kellgren-Lawrence grade 3 osteoarthritis in a 61-year-old woman who did not achieve sufficient pain relief with in-clinic injections and was not a surgical candidate for total knee arthroplasty. At examination, she reported focal pain in the inferior quadrant, with specific pain at the inferior lateral corner; therefore, geniculate cryoneurolysis was planned to include the inferior lateral geniculate nerve along the Gerdy tubercle, in addition to the standard treatment of superior medial, superior lateral, and inferior medial geniculate nerves. **(A)** Axial intraprocedural CT image shows the landmark for cryoneurolysis of the inferior lateral geniculate nerve, with the cryoprobe placed at the Gerdy tubercle of the tibia. **(B)** Axial intraprocedural CT image shows the cryoprobe in position to treat the inferior medial geniculate nerve. **(C)** Axial intraprocedural CT image shows the cryoprobes in position to treat the superior medial and superior lateral geniculate nerves.

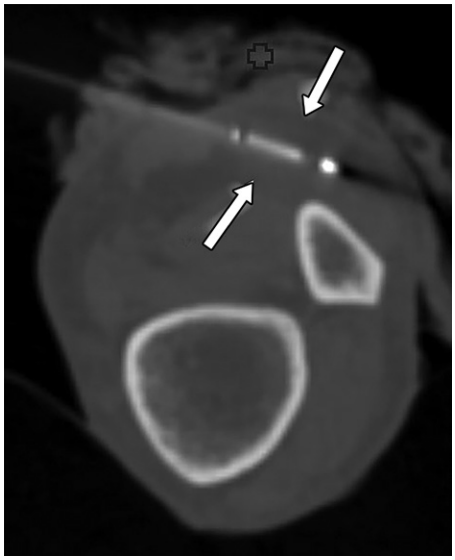

Figure 17. Axial intraprocedural CT image in a 72-year-old man who previously underwent open reduction of an ankle fracture shows the ablation zone (arrows) during a sural nerve cryoneurolysis procedure targeting the known course of the sural nerve, posteromedial to the fibula above the ankle, with warm saline solution–soaked gauze (open cross symbol) over the skin for protection from thermal injury.

Figure 18. Axial intraprocedural CT image in a 69-year-old woman with medial leg pain shows placement of a cryoablation probe during a saphenous nerve cryoneurolysis procedure targeting the known course of the saphenous nerve along the saphenous vein (blue oval).

with neuropathic pain (36,66). Likewise, anterior and posterior branches have been targeted using advanced imaging guidance (67,68). Posterior (Fig 19B), lateral, and anterior branches of the femoral nerve are readily targeted with CT for cryoneurolysis in the appropriate settings. Finneran and colleagues (69) performed a pilot study on patients with post–skin-grafting neuralgia showing pain improvements with lateral femoral cutaneous cryoneurolysis.

Peroneal Nerve.—The peroneal nerve is one of the two terminal branches of the sciatic nerve and supplies sensation and motor fibers to the lateral lower leg (70). The peroneal nerve ultimately supplies branches to the geniculate nerve complex, motor supply to the extensor compartment of the lateral leg, and cutaneous supply to the dorsum of the foot and lateral leg. Given its lateral location in the popliteal fossa, it is particularly vulnerable to injury associated with trauma. The same course also makes it a technically simple target for cryoneurolysis to manage neuropathic distribution in the appropriate location (Fig 20).

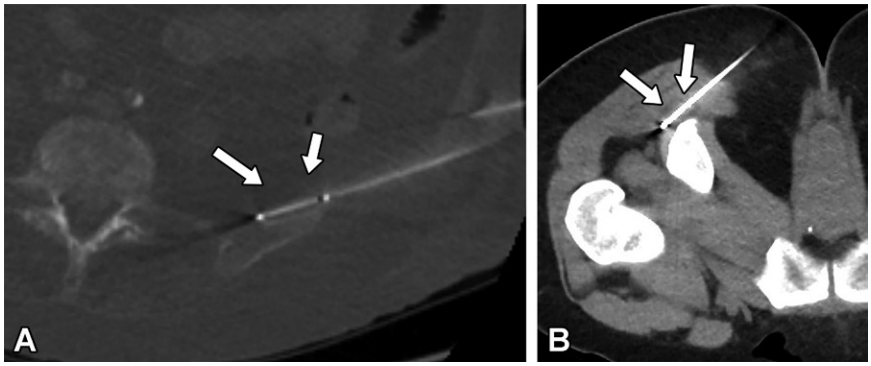

Figure 19. **(A)** Single axial intraprocedural CT image in an 80-year-old man with pain and a positive response to a diagnostic block shows the ablation zone (arrows) during a cryoneurolysis procedure targeting the known course of the lateral femoral cutaneous nerve anterior to the iliac bone in the pelvis. **(B)** Single axial intraprocedural CT image in a 26-year-old woman with pain and a positive response to a diagnostic block shows the ablation zone (arrows) during a cryoneurolysis procedure, targeting the known course of the posterior femoral cutaneous nerve posterior to the ischium in the pelvis.

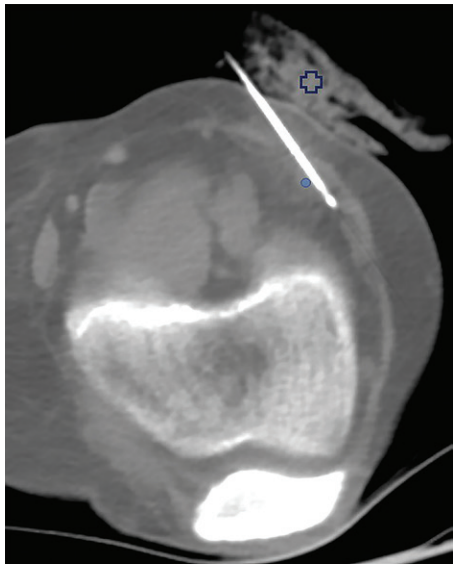

Figure 20. Single axial intraprocedural CT image in a 56-year-old woman with a 10-year history of posttraumatic neuropathic pain shows placement of a cryoablation probe during a cryoneurolysis procedure targeting the known course of the peroneal nerve posterolaterally in the popliteal fossa (blue oval). The open cross indicates warm saline-soaked gauze that protects the overlying skin from thermal injury.

CPT Code 0440T

CPT code 0440T is for percutaneous ablation of the upper extremity distal and peripheral nerves.

Ulnar Nerve.—Clinical indications for ulnar nerve cryoneurolysis include ulnar neuropathies caused by compression, entrapment, or mechanical compromise. The ulnar nerve courses posteromedially around the elbow to the medial lower arm (71). Patients present with neuropathic pain along the fourth and fifth fingers and medial arm, beginning at the elbow. Electrodiagnostic studies, patient history, and MR neurography are important to include central lesions such as cervical spine foraminal narrowing (72). In appropriate cases, the ulnar nerve may be safely targeted at the elbow for cryoneurolysis using imaging guidance (Fig 21).

Contraindications

The typical contraindications to percutaneous ablation apply, including coagulopathy, active infection, and anatomic inaccessibility. Additional contraindications specific to cryoablation include cryoglobulinemia, cold urticaria, and Raynaud disease.

Caution should be exercised when performing cryoablation in patients with active shingles, because the virus lives in the neuronal soma and/or the dorsal root ganglion. For example, for intercostal neuritis with a classic shingles rash, unless intentional dorsal root ganglion ablation is planned (73), neurolysis peripheral to the dorsal root ganglion may exacerbate shingles pain. Nerve blocks and antiviral therapies may allow more effective treatment in these patients.

Antineoplastic therapies are not a contraindication, and patients can often continue chemotherapy, immunotherapy, and radiation therapy without interruption. In fact, authors of many clinical trials allow cryoneurolysis to be performed, whereas a larger procedure (eg, implantation of an intrathecal drug delivery device) may otherwise cause a patient to exit the clinical trial.

Compared with radiofrequency neurolysis, cryoablation can be safely performed in patients with electromagnetic and cardiac implanted devices.

Complications

Complications of cryoneurolysis are rare. The most common complications include pain, swelling, and minor bleeding at the treatment

site. Only one incidence of a major complication has been reported, to our knowledge (ie, formation of an abscess at the treatment site) (74). The avoidance of nontarget ablation is critical, with special care taken to protect the skin. Rarely, especially if incomplete cryoneurolysis occurs, allodynia or even deafferentation pain can result, which may improve with administration of steroids, escalation of gabapentin and/or pregabalin, and nerve blockage that is central to the ablated region.

Practical Considerations: Building a Cryoneurolysis Practice

Interventional radiologists who are aware of nerve-directed strategies see eligible patients in their daily practice. In most settings, services are probably already provided under the auspices of a pain service line existing in the hospital. Early in the process of practice-building, opportunities to bundle procedures (eg, celiac plexus block at the time of biliary drain for pancreatic cancer, with low bile duct obstruction) may offer an avenue to serve the patient, reduce opioid dependence, allow faster discharge, and establish name recognition for interventional radiologists. Also, the ability to use CT to target deep structures accurately and swiftly, often with only local anesthesia compared with the usual monitored anesthesia care in the surgical setting, may provide another avenue to generate referrals. Radiologists in a robust palliative interventional radiology service line can work with palliative care specialists to reduce hospital stays and restore dignity for all patients, especially those approaching the end of life. Finally, it is important to collaborate closely with existing services, because complications or questions may arise, and good relationships always serve the best interests of the patient.

Conclusion

Interventional cryoneurolysis has expanded the available options to treat patients with conditions localized to a nerve or plexus, whether the condition is painful or nonpainful and whether it is benign or malignant. Advanced imaging-guidance techniques and protective maneuvers allow access to an expanding range of neural targets for neurolysis and neuroregeneration.

***Disclosures of conflicts of interest.*—E.B.F.** Member of the Board of Directors of the Accreditation Council for Continuing Medical Education; vice chair of the American College of Radiology General, Small, Emergency, and/or Rural Practice Commission; president elect of the Georgia Radiological Society. **N.N.** Holder of two patents for balloon catheters. **J.D.P.** Grants/grants pending from Boston Scientific Research, consultant for Boston Scientific and Varian, two patents pending, chief medical officer and cofounder of Focused Cryo.

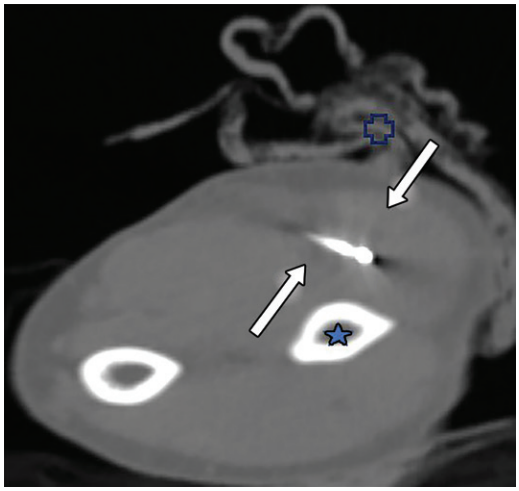

Figure 21. Single axial intraprocedural CT image in a 75-year-old man with a 20-year history of posttraumatic neuropathic pain shows the ablation zone (arrows) during a cryoneurolysis procedure targeting the known course of the ulnar nerve posterior to the ulna (☆) below the elbow. The open cross indicates warm saline-soaked gauze to protect the skin from thermal injury during the cryoneurolysis procedure.

References

1. U.S. Department of Health and Human Services. Pain Management Best Practices Inter-Agency Task Force Report. https://www.hhs.gov/opioids/prevention/pain-management-options/index.html. Published 2019. Accessed August 12, 2022.
2. Bittman RW, Behbahani K, Gonzalez F, Prologo JD. Interventional Cryoneurolysis: What Is the Same, What Is Different, What Is New? Semin Intervent Radiol 2019;36(5):374–380.
3. Cooper SM, Dawber RP. The history of cryosurgery. J R Soc Med 2001;94(4):196–201.
4. Lloyd JW, Barnard JDW, Glynn CJ. Cryoanalgesia. A new approach to pain relief. Lancet 1976;2(7992):932–934.
5. Jones MJT, Murrin KR. Intercostal block with cryotherapy. Ann R Coll Surg Engl 1987;69(6):261–262.
6. Evans PJD, Lloyd JW, Jack TM. Cryoanalgesia for intractable perineal pain. J R Soc Med 1981;74(11):804–809.
7. Prologo JD, Edalat F, Moussa M. Interventional Cryoneurolysis: An Illustrative Approach. Tech Vasc Interv Radiol 2020;23(4):100698.
8. Choi J, Min JG, Jopling JK, Meshkin S, Bessoff KE, Forrester JD. Intercostal nerve cryoablation during surgical stabilization of rib fractures. J Trauma Acute Care Surg 2021;91(6):976–980.
9. Filippiadis D, Ptohis N, Efthymiou E, Kelekis A. A Technical Report on the Performance of Percutaneous Cryoneurolysis of Splanchnic Nerves for the Treatment of Refractory Abdominal Pain in Patients with Pancreatic Cancer: Initial Experience. Cardiovasc Intervent Radiol 2021;44(5):789–794.
10. Finneran JJ IV, Ilfeld BM. Percutaneous cryoneurolysis for acute pain management: current status and future prospects. Expert Rev Med Devices 2021;18(6):533–543.
11. Zhou L, Kambin P, Casey KF, et al. Mechanism research of cryoanalgesia. Neurol Res 1995;17(4):307–311.
12. Trescot AM. Cryoanalgesia in interventional pain management. Pain Physician 2003;6(3):345–360.
13. Prologo JD, Johnson C, Hawkins CM, et al. Natural History of Mixed and Motor Nerve Cryoablation in Humans-A Cohort Analysis. J Vasc Interv Radiol 2020;31(6):912–916.e1.
14. Ilfeld BM, Preciado J, Trescot AM. Novel cryoneurolysis device for the treatment of sensory and motor peripheral nerves. Expert Rev Med Devices 2016;13(8):713–725.

15. Shah SB, Bremner S, Esparza M, et al. Does cryoneurolysis result in persistent motor deficits? A controlled study using a rat peroneal nerve injury model. Reg Anesth Pain Med 2020;45(4):287–292.
16. Hsu M, Stevenson FF. Wallerian degeneration and recovery of motor nerves after multiple focused cold therapies. Muscle Nerve 2015;51(2):268–275.
17. Moorjani N, Zhao F, Tian Y, Liang C, Kaluba J, Maiwand MO. Effects of cryoanalgesia on post-thoracotomy pain and on the structure of intercostal nerves: a human prospective randomized trial and a histological study. Eur J Cardiothorac Surg 2001;20(3):502–507.
18. Sunderland S. A classification of peripheral nerve injuries producing loss of function. Brain 1951;74(4):491–516.
19. Myers RR, Powell HC, Heckman HM, Costello ML, Katz J. Biophysical and pathological effects of cryogenic nerve lesion. Ann Neurol 1981;10(5):478–485.
20. Myers RR, Heckman HM, Powell HC. Axonal viability and the persistence of thermal hyperalgesia after partial freeze lesions of nerve. J Neurol Sci 1996;139(1):28–38.
21. Sunderland S. Nerves and nerve injuries. Baltimore, Md: Williams & Wilkins, 1968; 1161.
22. Cornman-Homonoff J, Formenti SC, Chachoua A, Madoff DC. Percutaneous Cryoablation for the Management of Chronic Pain Secondary to Locally Recurrent Rectal Cancer with Bowel and Nerve Root Involvement. J Vasc Interv Radiol 2018;29(9):1296–1298.
23. Chhabra A, Ahlawat S, Belzberg A, Andreseik G. Peripheral nerve injury grading simplified on MR neurography: As referenced to Seddon and Sunderland classifications. Indian J Radiol Imaging 2014;24(3):217–224.
24. Bittman RW, Peters GL, Newsome JM, et al. Percutaneous Image-Guided Cryoneurolysis. AJR Am J Roentgenol 2018;210(2):454–465.
25. Loev MA, Varklet VL, Wilsey BL, Ferrante FM. Cryoablation: a novel approach to neurolysis of the ganglion impar. Anesthesiology 1998;88(5):1391–1393.
26. Behbahani K, Chary A, Patel S, Mitchell JW, Fleishon H, Prologo JD. Percutaneous CT-Guided Cryoablation of the Celiac Plexus: A Retrospective Cohort Comparison with Ethanol. J Vasc Interv Radiol 2020;31(8):1216–1220.
27. Atwell TD, Wass CT, Charboneau JW, Callstrom MR, Farrell MA, Sengupta S. Malignant hypertension during cryoablation of an adrenal gland tumor. J Vasc Interv Radiol 2006;17(3):573–575.
28. Loukas M, Klaassen Z, Merbs W, Tubbs RS, Gielecki J, Zurada A. A review of the thoracic splanchnic nerves and celiac ganglia. Clin Anat 2010;23(5):512–522.
29. Comlek S. Pain Control with Splanchnic Neurolysis in Pancreatic Cancer Patients Unresponsive to Celiac Plexus Neurolysis. J Pain Res 2020;13:2023–2031.
30. Amr SA, Reyad RM, Othman AH, et al. Comparison between radiofrequency ablation and chemical neurolysis of thoracic splanchnic nerves for the management of abdominal cancer pain, randomized trial. Eur J Pain 2018;22(10):1782–1790.
31. Grigoriadis S, Tsitskari M, Ioannidi M, et al. Computed Tomography-Guided Percutaneous Radiofrequency Ablation of the Splanchnic Nerves as a Single Treatment for Pain Reduction in Patients with Pancreatic Cancer. Diagnostics (Basel) 2021;11(2):303.
32. Casteleijn NF, van Gastel MD, Blankestijn PJ, et al. Novel treatment protocol for ameliorating refractory, chronic pain in patients with autosomal dominant polycystic kidney disease. Kidney Int 2017;91(4):972–981.
33. 2022 Physician Fee Schedule. CMS 1751F - 2022 Conversion Factor 33.59. Centers for Medicare & Medicaid Services. https://www.cms.gov/medicaremedicare-fee-service-paymentphysicianfeeschedpfs-federal-regulation-notices/cms-1751-f. Accessed August 12, 2022.
34. Coding Clarification: Reporting Code 64640 for Cryoneurolysis (Aprl 2019). CPT Assistant 2019;29(4):9. https://www.findacode.com/newsletters/ama-cpt-assistant/coding-clarification-reporting-code-64640-for-cryoneurolysis-april-2019-4.html. Accessed August 12, 2022.
35. American Medical Association. CPT Editorial Summary of Panel Actions February 2021. https://www.ama-assn.org/system/files/2021-03/february-2021-summary-panel-actions.pdf. Accessed August 12, 2022.
36. Finneran JJ IV, Schaar AN, Swisher MW, et al. Percutaneous cryoneurolysis of the lateral femoral cutaneous nerve for analgesia following skin grafting: a randomized, controlled pilot study. Reg Anesth Pain Med 2022;47(1):60–61.
37. Prologo JD, Snyder LL, Cherullo E, Passalacqua M, Pirasteh A, Corn D. Percutaneous CT-guided cryoablation of the dorsal penile nerve for treatment of symptomatic premature ejaculation. J Vasc Interv Radiol 2013;24(2):214–219.
38. Schraffordt SE, Tjandra JJ, Eizenberg N, Dwyer PL. Anatomy of the pudendal nerve and its terminal branches: a cadaver study. ANZ J Surg 2004;74(1-2):23–26.
39. Hibner M, Desai N, Robertson LJ, Nour M. Pudendal neuralgia. J Minim Invasive Gynecol 2010;17(2):148–153.
40. Labat JJ, Riant T, Robert R, Amarenco G, Lefaucheur JP, Rigaud J. Diagnostic criteria for pudendal neuralgia by pudendal nerve entrapment (Nantes criteria). Neurourol Urodyn 2008;27(4):306–310.
41. Venturi M, Boccasanta P, Lombardi B, Brambilla M, Contessini Avesani E, Vergani C. Pudendal Neuralgia: A New Option for Treatment? Preliminary Results on Feasibility and Efficacy. Pain Med 2015;16(8):1475–1481.
42. Prologo JD, Manyapu S, Bercu ZL, Mittal A, Mitchell JW. Percutaneous CT-Guided Cryoablation of the Bilateral Pudendal Nerves for Palliation of Intractable Pain Related to Pelvic Neoplasms. Am J Hosp Palliat Care 2020;37(8):619–623.
43. Alkatout I, Wedel T, Pape J, Possover M, Dhanawat J. Review: Pelvic nerves - from anatomy and physiology to clinical applications. Transl Neurosci 2021;12(1):362–378.
44. Sultan AH, Kamm MA, Hudson CN. Pudendal nerve damage during labour: prospective study before and after childbirth. Br J Obstet Gynaecol 1994;101(1):22–28.
45. Ciocanel O, Power K, Eriksen A. Interventions to Treat Erectile Dysfunction and Premature Ejaculation: An Overview of Systematic Reviews. Sex Med 2019;7(3):251–269.
46. Mohamed AH, Mohamud HA, Yasar A. The prevalence of premature ejaculation and its relationship with polygamous men: a cross-sectional observational study at a tertiary hospital in Somalia. BMC Urol 2021;21(1):175.
47. Kosugi S, Hashiguchi S, Nishimura D, et al. Neurolysis targeting both the aorticorenal ganglia and lumbar sympathetic plexus for kidney tumor-related pain. Pain Med 2015;16(1):202–203.
48. Koethe Y, Mannes AJ, Wood BJ. Image-guided nerve cryoablation for post-thoracotomy pain syndrome. Cardiovasc Intervent Radiol 2014;37(3):843–846.
49. Tanaka A, Al-Rstum Z, Leonard SD, et al. Intraoperative Intercostal Nerve Cryoanalgesia Improves Pain Control After Descending and Thoracoabdominal Aortic Aneurysm Repairs. Ann Thorac Surg 2020;109(1):249–254.
50. Bauman ZM, Loftus J, Raposo-Hadley A, et al. Surgical stabilization of rib fractures combined with intercostal nerve cryoablation proves to be more cost effective by reducing hospital length of stay and narcotics. Injury 2021;52(5):1128–1132.
51. Daubié S, Pilleul F, Thivolet A, et al. Cryoneurolysis in Patients with Dorsal Neuropathic Pain Secondary to Tumor Invasion. J Vasc Interv Radiol 2020;31(6):917–924.
52. Kral JG, Paez W, Wolfe BM. Vagal nerve function in obesity: therapeutic implications. World J Surg 2009;33(10):1995–2006.
53. Prologo JD, Lin E, Horesh Bergquist S, et al. Percutaneous CT-Guided Cryovagotomy in Patients with Class I or Class II Obesity: A Pilot Trial. Obesity (Silver Spring) 2019;27(8):1255–1265.
54. Prologo JD. Percutaneous CT-Guided Cryovagotomy. Tech Vasc Interv Radiol 2020;23(1):100660.
55. Prologo JD, Gilliland CA, Miller M, et al. Percutaneous Image-Guided Cryoablation for the Treatment of Phantom Limb Pain in Amputees: A Pilot Study. J Vasc Interv Radiol 2017;28(1):24–34.e4.
56. von Falck C, Orgel M, Wacker F, Aschoff HH, Krettek C, Ringe KI. Icing the Pain-Ultrasound-Guided Cryoablation of Symptomatic Post-Amputation Stump Neuroma. Cardiovasc Intervent Radiol 2022;45(2):223–227.

57. Bagla S, Piechowiak R, Sajan A, Orlando J, Hartman T, Isaacson A. Multicenter Randomized Sham Controlled Study of Genicular Artery Embolization for Knee Pain Secondary to Osteoarthritis. J Vasc Interv Radiol 2022;33(1):2–10.e2.
58. Tran J, Peng PWH, Lam K, Baig E, Agur AMR, Gofeld M. Anatomical Study of the Innervation of Anterior Knee Joint Capsule: Implication for Image-Guided Intervention. Reg Anesth Pain Med 2018;43(4):407–414.
59. Fonkoué L, Behets C, Kouassi JK, et al. Distribution of sensory nerves supplying the knee joint capsule and implications for genicular blockade and radiofrequency ablation: an anatomical study. Surg Radiol Anat 2019;41(12):1461–1471.
60. Nygaard NB, Koch-Jensen C, Vægter HB, Wedderkopp N, Blichfeldt-Eckhardt M, Gram B. Cryoneurolysis for the management of chronic pain in patients with knee osteoarthritis; a double-blinded randomized controlled sham trial. BMC Musculoskelet Disord 2021;22(1):228.
61. Mihalko WM, Kerkhof AL, Ford MC, Crockarell JR Jr, Harkess JW, Guyton JL. Cryoneurolysis before Total Knee Arthroplasty in Patients With Severe Osteoarthritis for Reduction of Postoperative Pain and Opioid Use in a Single-Center Randomized Controlled Trial. J Arthroplasty 2021;36(5):1590–1598.
62. Majewski M, Rohrbach M, Czaja S, Ochsner P. Avoiding sural nerve injuries during percutaneous Achilles tendon repair. Am J Sports Med 2006;34(5):793–798.
63. Bridges D, Thompson SW, Rice AS. Mechanisms of neuropathic pain. Br J Anaesth 2001;87(1):12–26.
64. Prologo JD, Johnson C, Hawkins CM, et al. Natural History of Mixed and Motor Nerve Cryoablation in Humans-A Cohort Analysis. J Vasc Interv Radiol 2020;31(6):912–916.e1.
65. Radnovich R, Scott D, Patel AT, et al. Cryoneurolysis to treat the pain and symptoms of knee osteoarthritis: a multicenter, randomized, double-blind, sham-controlled trial. Osteoarthritis Cartilage 2017;25(8):1247–1256.
66. Finneran JJ, Swisher MW, Gabriel RA, et al. Ultrasound-Guided Lateral Femoral Cutaneous Nerve Cryoneurolysis for Analgesia in Patients With Burns. J Burn Care Res 2020;41(1):224–227.
67. Joshi DH, Thawait GK, Del Grande F, Fritz J. MRI-guided cryoablation of the posterior femoral cutaneous nerve for the treatment of neuropathy-mediated sitting pain. Skeletal Radiol 2017;46(7):983–987.
68. Dalili D, Ahlawat S, Rashidi A, Belzberg AJ, Fritz J. Cryoanalgesia of the anterior femoral cutaneous nerve (AFCN) for the treatment of neuropathy-mediated anterior thigh pain: anatomy and technical description. Skeletal Radiol 2021;50(6):1227–1236.
69. Finneran JJ IV, Schaar AN, Swisher MW, et al. Percutaneous cryoneurolysis of the lateral femoral cutaneous nerve for analgesia following skin grafting: a randomized, controlled pilot study. Reg Anesth Pain Med 2021;47(1):60–61.
70. Knipe H, Bickle I. Common Peroneal Nerve. Reference article, Radiopaedia.org. Published April 3, 2021. Accessed August 12, 2022.
71. Caliandro P, La Torre G, Padua R, Giannini F, Padua L. Treatment for ulnar neuropathy at the elbow. Cochrane Database Syst Rev 2016;11(11):CD006839.
72. Dy CJ, Mackinnon SE. Ulnar neuropathy: evaluation and management. Curr Rev Musculoskelet Med 2016;9(2):178–184.
73. Kim YH, Lee CJ, Lee SC, et al. Effect of pulsed radiofrequency for postherpetic neuralgia. Acta Anaesthesiol Scand 2008;52(8):1140–1143.
74. Cahani D, Chacko J, Hahn B. Myonecrosis: A Rare Complication of Cryoneurolysis. J Emerg Med 2019;57(3):e73–e76.